



Vulvo-vaginal atrophy: A new treatment modality using thermo-ablative fractional CO₂ laser



Antonino Perino^a, Alberto Calligaro^b, Francesco Forlani^{a,*}, Corrado Tiberio^a, Gaspare Cucinella^a, Alessandro Svelato^a, Salvatore Saitta^c, Gloria Calagna^a

^a Department of Obstetrics and Gynaecology, University Hospital "P. Giaccone", Palermo, Italy

^b Department of Public Health, Experimental and Forensic Medicine, Unit of Histology and Embryology University of Pavia, Pavia, Italy

^c Department of Human Pathology, School and Division of Allergy and Clinical Immunology, University of Messina, Messina, Italy

ARTICLE INFO

Article history:

Received 22 July 2014

Received in revised form 8 December 2014

Accepted 11 December 2014

Keywords:

Vulvo-vaginal atrophy

Laser treatment

Menopause

ABSTRACT

Objective: To evaluate the efficacy and feasibility of thermo-ablative fractional CO₂ laser for the treatment of symptoms related to vulvo-vaginal atrophy (VVA) in post-menopausal women.

Methods: From April 2013 to December 2013, post-menopausal patients who complained of one or more VVA-related symptoms and who underwent vaginal treatment with fractional CO₂ laser were enrolled in the study. At baseline (T0) and 30 days post-treatment (T1), vaginal status of the women was evaluated using the Vaginal Health Index (VHI), and subjective intensity of VVA symptoms was evaluated using a visual analog scale (VAS). At T1, treatment satisfaction was evaluated using a 5-point Likert scale.

Results: During the study period, a total of 48 patients were enrolled. Data indicated a significant improvement in VVA symptoms (vaginal dryness, burning, itching and dyspareunia) ($P < 0.0001$) in patients who had undergone 3 sessions of vaginal fractional CO₂ laser treatment. Moreover, VHI scores were significantly higher at T1 ($P < 0.0001$). Overall, 91.7% of patients were satisfied or very satisfied with the procedure and experienced considerable improvement in quality of life (QoL). No adverse events due to fractional CO₂ laser treatment occurred.

Conclusion: Thermo-ablative fractional CO₂ laser could be a safe, effective and feasible option for the treatment of VVA symptoms in post-menopausal women.

© 2014 Elsevier Ireland Ltd. All rights reserved.

1. Introduction

Before the climacteric period, the vagina is composed of thick layers of healthy cells, and estrogen encourages the growth and development of these cells; therefore, the vaginal epithelium remains multi-layered, and vaginal walls are supple and elastic [1,2]. The progressive reduction in circulating estrogen, which occurs following the cessation of ovarian function during menopause, induces various metabolic and tissue changes, which are most prominent in the genital tract due to its particular sensitivity to variations in sex hormone levels [2,3]. Vulvo-vaginal atrophy (VVA) is a progressive, chronic condition that manifests as involution of the vulvo-vaginal mucous membranes and tissues due to the menopausal drop in estrogen levels [4,5].

Typical symptoms of VVA, which reflect these vulvo-vaginal morpho-functional changes, include vaginal dryness, itching, burning, irritation, dysuria and dyspareunia [6,7]. In particular, the

vaginal walls appear thinner and less elastic with loss of rugations. The entire vaginal canal becomes narrower and shorter. The vaginal surface appears dry and friable and often bleeds after minimal trauma. The vulvar area, particularly the clitoris, becomes atrophic and more vulnerable [8].

Vaginal atrophy can worsen over the years and negatively influence quality of life (QoL) [9]. Approximately 50% of postmenopausal women experience symptoms of VVA [10,11], which can range from mild (*annoying*) to severe (*very bothersome*).

These symptoms may cause significant emotional distress and may result in sexual dysfunction. The burden of VVA on the individual and the population is greater than physicians may realize, especially due to socio-cultural barriers and a lack of access to health care in certain countries [12].

Because of the progressive aging of the general population, women may complain of vaginal aging symptoms (itching, burning, reduced lubrication, superficial and/or severe dyspareunia related to vulvovaginal atrophy) for more than one third of their lives [13].

Several therapeutic options are available to alleviate VVA symptoms, including non-hormonal products for mild cases, vaginal hormone therapy for persistent symptoms, and systemic hormonal

* Corresponding author.

E-mail address: forlani81@gmail.com (F. Forlani).

replacement therapy (HRT) as a broader approach for severe symptoms [2,14]. Lubricants have been demonstrated to decrease vaginal irritation during sexual activity but do not provide a long-term solution [15]. Few clinical data have indicated that vaginal moisturizers improve VVA symptoms [16]. Systemic HRT may be considered for climacteric symptoms in the absence of contraindications; however, this type of treatment is associated with more side effects than the local administration of HRT and is not recommended unless vasomotor symptoms need to be controlled [2,14]. Several clinical trials have demonstrated the efficacy of low-dose local estrogen therapies in women with only VVA symptoms in the absence of contraindications. However, limited data are available on the long-term safety of these therapies, and no information is available on high-risk patients [2,14,17].

Moreover, the major drawback of this approach is the recurrence of symptoms once treatment has been suspended, and this treatment is only effective in the superficial layer of the vaginal walls [18].

In recent years, there has been a greater demand for a safe, long-term therapeutic option that can effectively treat the deeper layers of the vaginal mucosa in addition to the epithelium. By applying the principles of regenerative and anti-aging medicine to the vaginal mucosa, the use of fractional CO₂ laser may be extended to treat patients with VVA [19].

As demonstrated in other areas of the body [20–24], this system induces the topical remodeling of connective tissue and the production of collagen and elastic fibers. Based on results that were obtained on the skin, we applied a fractional CO₂ laser treatment that was specifically designed for the vaginal mucosa to determine the safety and efficacy of this treatment in improving VVA symptoms in postmenopausal women.

2. Materials and methods

2.1. Patients

For this observational pilot study, post-menopausal patients who complained of one or more symptoms related to VVA and who underwent vaginal treatment with fractional CO₂ laser from April 2013 to December 2013 were included in the study. The inclusion criteria consisted of menopausal status (including early forms), one or more vulvo-vaginal symptoms (e.g., itching, burning, reduced lubrication, superficial and/or severe dyspareunia), and non-response to previous estrogen or local therapies. Patients with active genital infections, pelvic organ prolapse (POP) stage >II (according to the Half Way System for the quantification of POP) [25] and/or the use of HRT (systemic or local) up to 6 months before the study recruitment period were excluded from the study. Patients who used vaginal lubricants or any other local preparations were asked to suspend the application of these treatments and were included in the study after 30 days. Women who were using psychotropic drugs were excluded. The study was approved by the Hospital Research Committee. All patients who were recruited for the study signed an informed consent form.

2.2. Laser device

A fractional CO₂ laser system (SmartXide2V₂LR, Deka m.e.l.a., Florence, Italy) was equipped with a VulvoVaginal Laser Reshaping (V₂LR) scanning system and appropriate probes for the vaginal area. This treatment modality is based on the interaction between a specific CO₂ pulsed laser and the vaginal mucosa. A laser beam is emitted fractionally, and the CO₂ laser is focused in small spots (called DOTs) that are separated by healthy tissue. The laser beam penetrates the tissue and releases heat only when the set depth is

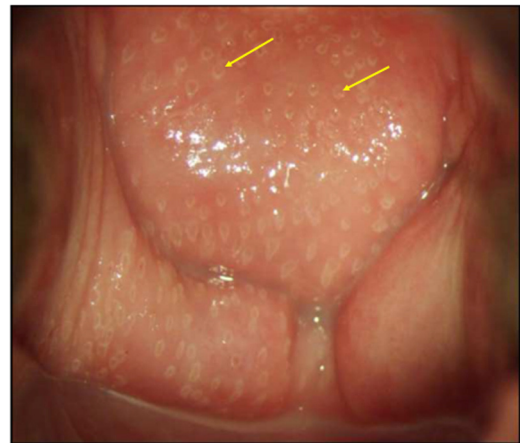

Fig. 1. Colposcopic view of vaginal walls immediately after a session of fractional CO₂ laser therapy. Arrows indicate macroscopic ablation zones.



Fig. 2. New specifically designed vaginal probe with a pyramidal tip that allows laser beam emission at 360°.

reached. With software control and a radiofrequency system that feeds the laser source, it is possible to select the *D-Pulse* mode, the depth (*SmartStak* parameter, from 1 to 3) and the quantity (*power*, *dwell time* and *spacing*) of heat to be transferred to the tissue. The *SmartStak* function allows for careful control of vaporization depth and thermal action. Successive pulses are emitted in the same area for a *Stack* variable of 1–3 (in the vaginal application). This procedure allows the mucosa to cool between two successive pulses and minimizes thermal damage.

Every pulse is composed of a constant high-energy peak power to produce rapid ablation of the epithelial component of atrophic mucosa, followed by longer emission times (*dwell time*) that allow the CO₂ laser to penetrate further into the mucosa.

The pulses are distributed over the vaginal wall and are spaced (*DOT spacing*) to cover the entire treatment area. A specific probe is used to deliver the pulses, which allows for energy emission at 360° (Fig. 1). In this study, a calibrated probe was specifically utilized for vaginal application, and this probe can be easily inserted into the vaginal canal (Fig. 2). The laser is projected toward a 45°-oriented mirror that is placed at the tip of the probe to be reflected on the vaginal walls but not the uterine cervix. To completely treat the vaginal area, it is necessary to emit many laser spots while progressively extracting the probe from the vaginal fundus. Each treatment spot consists of two passages. After the first energy release, the probe is rotated approximately 2 cm (using the regulatory tool) clockwise while remaining at the same vaginal distance.

2.3. Laser treatment

Each patient was treated with the fractional CO₂ laser system using the vaginal probe.

In all cases, introduction of the probe into the vaginal canal was successful, and treatment was completed. In several difficult cases, a gel was applied to the top of the probe to facilitate entry. All patients underwent a complete cycle of three treatment sessions that were spaced over a period of at least 30 days. For each patient, a Pap test and vaginal swabbing were performed to rule

out local lesions or infections. The procedure was performed in the outpatient clinic by two operators (A.P. and G.C.), and the patients did not receive analgesia or anesthesia. Ex vivo results obtained from vaginal wall specimens were used to design the laser device (unpublished data). According to these data, the settings for intravaginal treatment were a DOT power of 40 watts, a dwell time of 1000 μ s, DOT spacing of 1000 μ m, SmartStak 2 and the D-Pulse mode. When necessary, the DOT power was reduced to 30 or 20 watts for the treatment of the vaginal introitus, which is a highly sensitive area. With these parameters, the patients did not experience any discomfort during the application of the fractional CO₂ laser to the vaginal mucosa similar to a previous clinical experience (personal unpublished data). During all treatment sessions, the following two-phase protocol was followed:

- 1) positioning of the speculum and observation of the vagina using colposcopic vision (Vaginal Health Index, VHI, scoring was performed during this phase);
- 2) careful introduction of the probe deep into the vaginal canal before start of procedure.

No local therapy was recommended after the laser sessions. To avoid vaginal irritation during the healing process, patients were advised to avoid coital activity for at least 1 week following each laser application. Any secondary or collateral effects of the treatment were recorded. For study analysis, two relevant time points were considered for the evaluation of treatment results: baseline (T0) and 30 days after the last laser application (T1).

2.4. Study data

Relevant demographic characteristics, pre-treatment clinical data and inclusion/exclusion criteria were recorded at T0. At T0 and T1, vaginal status of the patients was evaluated using VHI scores (obtained using colposcopic vision), which consisted of the following 5 parameters: elasticity, fluid volume, pH, epithelial integrity and moisture. Each parameter was graded from 1 (worst condition) to 5 (best condition) [26,27]. The “elasticity” parameter was mainly evaluated through introduction and positioning of the speculum in the vaginal canal, as, based on VVA severity, it was possible to

observe less vaginal distensibility and pain in this phase; moreover, a cotton tip, pressed to the vaginal walls, was used to add further information regarding vaginal “elasticity”.

In addition, the “epithelial integrity” parameter was evaluated during the introduction of the speculum, observing the tendency to bleed of the vaginal walls in this phase. The “vaginal pH” parameter was evaluated using a colorimetric test. The “fluid volume” parameter was evaluated using a cotton tip applicator passed over the vaginal walls, and to estimate the “moisture” parameter it was sufficient to observe the vaginal surface using a colposcopic view.

Intensity of VVA symptoms was also evaluated (vaginal itching, vaginal burning, vaginal dryness and dyspareunia) using a visual analog scale (VAS), which is based on a score from 1 to 10, where 1 indicates the absence of symptoms and 10 indicates severe symptoms (“as bad as it could be”).

At T1, treatment satisfaction was evaluated using a 5-point Likert scale (very satisfied, satisfied, uncertain, dissatisfied and very dissatisfied). Treatment was considered satisfactory when patient answers were “very satisfied” or “satisfied”. Eventual adverse events which occurred or were referred by patients (during, immediately after treatment sessions, and until end of study) were recorded. We considered any disorder, discomfort or injury, both local and general, arising in relation to the application of the vaginal fractional CO₂ laser as an adverse event.

2.5. Statistical analysis

Statistical analysis was performed using SPSS for Windows (version 17.0). Data are presented as the median and interquartile range (IQR). Differences in VAS scores at T0 and T1 were analyzed using the Wilcoxon test. Statistical significance was set at $P < 0.05$.

3. Results

A total of 48 patients were enrolled in the study; median age was 56 years. All demographic characteristics of the patients are reported in Table 1.

Duration of menopausal status was <2 years in 9 cases (18.7%), between 2 and 5 years in 22 cases (45.8%) and >5 years in 17 cases (35.4%). Duration of therapy prior to laser CO₂ treatment

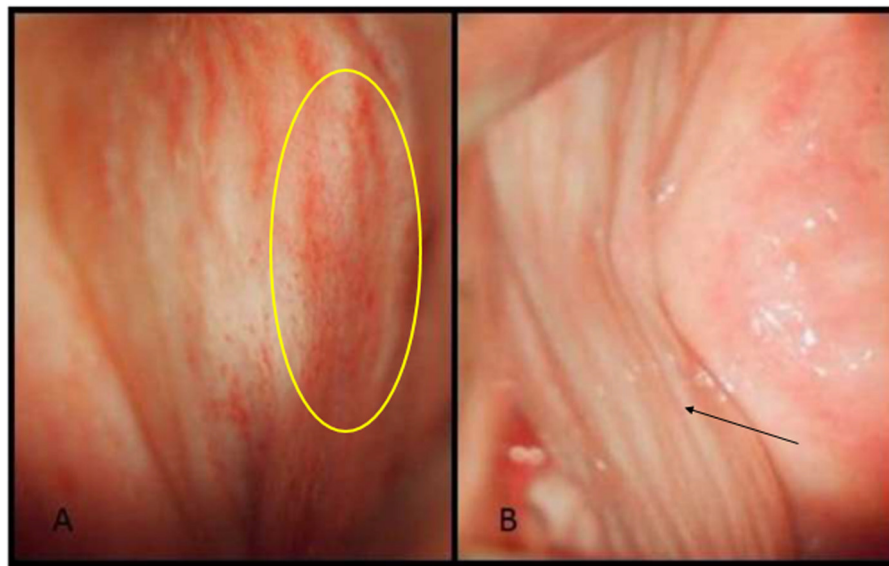


Fig. 3. (A and B). At T0 before laser treatment, vaginal walls are thinner and less elastic with loss of rugations (A); yellow ring highlights petechial atrophy. At T1, complete vaginal resurfacing effect is observed (B); arrow indicates restored vaginal mucosa. (For interpretation of the references to color in this figure legend, the reader is referred to the web version of this article.)

Table 1
Demographic characteristics of the study population.

Age (median/IQR)	56/7.75
Body Mass Index (median/IQR)	24.3/3.25
Parity (median/IQR)	1/1.75
Smokers (n, %)	9 (18.7)
Previous HRT (n, %)	11 (22.9)
Previous vaginal estriol (n, %)	10 (20.8)
Previous vaginal hyaluronic acid (n, %)	4 (8.3)
Previous vaginal estriol and hyaluronic acid (n, %) ^a	19 (39.6)
Other previous therapy (<i>Aloe vera</i> , <i>vitamins</i> , <i>phytoestrogens</i>)	4 (8.3)

^a Different courses of treatment.

Table 2
Changes in the VHI score and the intensity of VVA symptoms.

	T0	T1
VHI score	10.5/3	21.5/2
Vaginal dryness ^a	8/2	2/1
Vaginal burning ^a	6/2	2/1
Vaginal itching ^a	6/1.75	2/0.75
Dyspareunia ^a	8/2	3/1

Note: Data are presented as median/IQR.

^a Measured on VAS scale (range 1–10).

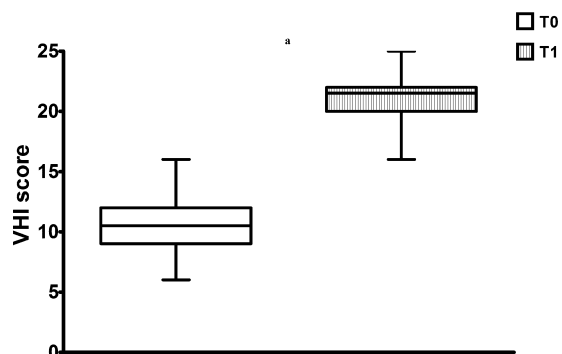


Fig. 4. Boxes and whiskers represent the medians, 1st and 3rd quartiles, and minimum and maximum values of VHI scores. Statistical analysis was performed using the Wilcoxon test. ^a $P < 0.0001$.

was variable: <12 months in 8 patients (16.7%), between 12 and 24 months in 27 patients (56.2%), >24 months in 13 patients (27.1%).

In 22.9% of cases, patients had used systemic HRT with no benefit, before vaginal CO₂ laser treatment.

All enrolled patients completed the study protocol and final evaluation at T1 (Fig. 3). Changes in VHI scores and intensity of VVA symptoms at each time point are described in Table 2.

VHI scores at T1 were statistically higher than at T0 (21.5/2 vs. 10.5/3; $P < 0.0001$) (Fig. 4). For each VAS parameter considered in the analysis, a statistically significant improvement was recorded (dryness: 8/2 vs. 2/1; burning: 6/2 vs. 2/1; itching: 6/1.75 vs. 2/0.75, dyspareunia 8/2 vs. 3/1; $P < 0.0001$) (Fig. 5).

Patient satisfaction with laser procedure at T1 was as follows: 18 (37.5%) patients were very satisfied, 26 (54.2%) were satisfied, 3 (6.2%) were uncertain, 1 (2.1%) was dissatisfied and 0 were very dissatisfied.

Mean time required for each treatment session was 6 min (± 2 min), and no significant differences were observed between patients or between the sessions for the same patient. No adverse events due to fractional CO₂ laser treatment occurred. In no case was it necessary to stop the procedure because of patient pain or intolerance.

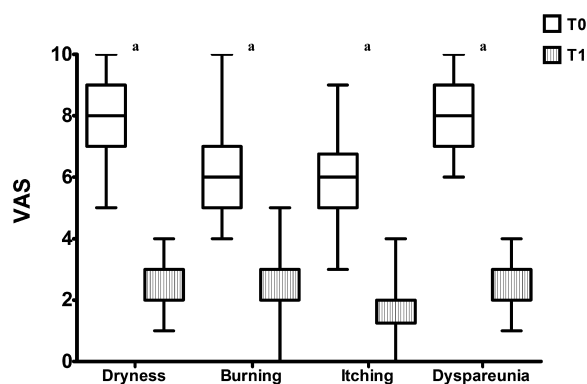


Fig. 5. Boxes and whiskers represent the medians, 1st and 3rd quartiles, and minimum and maximum values for VAS scores (dryness, burning, itching, and dyspareunia). Statistical analysis was performed using the Wilcoxon test. ^a $P < 0.0001$.

4. Discussion

Over the past decade, the use of CO₂ laser has been widely adopted in medicine, especially in dermatology and plastic surgery [20–24,28]. This laser consists of a CO₂ ray (infrared ray), which generates heat and vaporizes the water content of target cells.

The effect is specific to the superficial layer of skin and does not cause damage to surrounding tissue. In 2003, Capron et al. identified the principal mechanism of the laser-effect, which is based on the generation of supra-physiologic levels of heat that induce a local heat shock response [28]. This response is a temporary and rapid change in cellular metabolism characterized by the massive production of heat shock proteins (HSPs), a group of proteins that are present in the cells of all organisms. HSPs have a chaperone role in protecting the extracellular environment from thermal insults [29]. Expression patterns change when cells are exposed to elevated temperatures or other stressors [30,31]. Heat stress causes several proteins in cells to denature, and HSPs protect cells by translocating or re-folding stress-denatured proteins, thereby preventing inappropriate aggregation [32,33]. These proteins play a role in the coordinated expression of many growth factors, such as TGF- β , which is a key element in the inflammatory response and fibrogenic process [34].

The fractional CO₂ laser system consists of two phases: acute thermo-ablative damage, followed by proliferation. Application of the laser stimulates the synthesis of new mature collagen and matrix substance components in the treated site. This laser technology is used in the vagina to achieve “regeneration” with a minimally invasive procedure, thereby improving elasticity and hydration of the vaginal walls and relieving discomfort in menopausal women. Approximately 50% of otherwise healthy women over 60 years of age have symptoms that are related to vaginal atrophy [4,35]. Dryness, pain and dyspareunia are consistently associated with a marked negative impact on sex and relationships, which causes decreased QoL [36].

In 2011, Gaspar et al. first demonstrated significant histological improvement in vaginal biopsy specimens that had been treated with fractional microablative CO₂ laser in combination with platelet-rich plasma. They observed beneficial effects in the 3 layers of the vaginal wall in contrast to estrogens or other local therapies that only treat the epithelium [19]. The fractional laser system can irradiate deeper layers of the vaginal wall and ultimately reactivate the extracellular matrix and collagen synthesis, which leads to the recovery of vaginal tissue trophism with minimal trauma to superficial areas.

Salvatore et al. recently published a pilot study on the treatment of VVA in postmenopausal women using fractional CO₂ laser

[37]. Their results demonstrated that laser treatment was effective in improving VVA symptoms (vaginal dryness, vaginal burning, vaginal itching, dyspareunia, and dysuria; $P < 0.001$) and VHI scores (13.1 ± 2.5 at baseline versus 23.1 ± 1.9 ; $P < 0.001$) at a 12-week follow-up.

The data from our study indicate a significant improvement in VVA symptoms ($P < 0.0001$) in the women who underwent 3 sessions of vaginal fractional CO₂ laser treatment. Moreover, a significant increase in vaginal health scores was observed at T1 ($P < 0.0001$). In addition, 91.7% of the patients declared that they were satisfied or very satisfied with the procedure, which corresponded to a considerable improvement in QoL. Duration of the vaginal changes that were induced by the laser application must be clarified. Salvatore et al. confirmed that the effect on collagen remodeling, which they had preliminarily demonstrated in ex vivo vaginal specimens, was similar to what has been observed in vivo at the skin level [38,39].

This collagen remodeling in the skin was present 3 months after the last laser session [40]. These data support the long-term effect of the treatment. The principal limitation of this study is the absence of a control group of patients, which uses traditional local estrogen therapy. Secondary, the study considers a small sample size and lacks long-term follow-up (at least 1 year). Therefore, in light of these preliminary results, we will proceed to a randomized case-control study, including a follow-up at 12 months after the last laser treatment session. Furthermore, it would be interesting to extend the use of vaginal CO₂ laser to women with severe contraindications to hormonal treatments, such as cancer survivors, for whom laser treatment may be utilized as “non-hormonal therapy”.

Special attention should be paid to patients with estrogen-dependent malignancies who are at high risk of severe VVA symptoms and sexual dysfunction [41]. Literature has demonstrated an increase in the incidence and progression of gynecological symptoms following chemotherapy and/or endocrine therapy.

Approximately 50–75% of breast cancer survivors experience one or more urogenital symptoms. Because of the potential for reduced QoL and poor compliance, treatment of these side effects is a fundamental component of patient care. Topical estrogen therapy is currently the most common approach for these patients; however, clinicians may be unaware of the guidelines regarding the administration of these therapies in breast and genital cancer survivors [2,42]. For these patients, vaginal CO₂ laser treatment may be a viable option.

Finally, an innovative application of fractional CO₂ laser treatment is in laser assisted topical drug delivery, which may enhance therapeutic effects on target tissue [43].

5. Conclusion

For the treatment of women with severe urogenital symptoms who do not benefit from lifestyle changes, vaginal moisturizers or local estrogen therapy, clinicians should consider the use of vaginal fractional CO₂ laser treatment. Our results suggest that thermablative fractionated CO₂ laser could be a safe, well-tolerated and effective alternative for the relief of VVA symptoms in postmenopausal women.

Contributors

AP and GC performed the laser treatment, conceived and wrote the paper; FF and AS performed the acquisition of data; CT and GC performed the interpretation of data; SS performed the statistical analysis.

Competing interests

The authors declare no conflict of interest.

Funding

None.

References

- [1] Suckling J, Lethaby A, Kennedy R. Local oestrogen for vaginal atrophy in postmenopausal women. *Cochrane Database Syst Rev* 2003;CD001500.
- [2] Sturdee DW, Panay N, International Menopause Society Writing Group. Recommendations for the management of postmenopausal vaginal atrophy. *Climacteric* 2010;13(6):509–22.
- [3] Fredman M. Vaginal pH, estrogen and genital atrophy. *Menopaus Manage* 2008;17:9–13.
- [4] Castelo-Branco C, Cancelo MJ, Villero J, Nohales F, Julià MD. Management of post-menopausal vaginal atrophy and atrophic vaginitis. *Maturitas* 2005;52:S46–52.
- [5] Archer DF. Efficacy and tolerability of local estrogen therapy for urogenital atrophy. *Menopause* 2010;17:194–203.
- [6] Panay N, Maamari R. Treatment of postmenopausal vaginal atrophy with 10 µg estradiol vaginal tablets. *Menopaus Int* 2012;18:15–9.
- [7] Parish SJ, Nappi RE, Krychman ML, Kellogg-Spadt S, Simon JA, Goldstein JA, et al. Impact of vulvovaginal health on postmenopausal women: a review of surveys on symptoms of vulvovaginal atrophy. *Int J Women's Health* 2013;5:437–47.
- [8] Mehta A, Bachmann G. Vulvovaginal complaints. *Clin Obstet Gynecol* 2008;51(3):549–55.
- [9] Leiblum S, Bachman G, Kemmann E, Colburn D, Swartzman L. Vaginal atrophy in the postmenopausal woman. The importance of sexual activity and hormones. *JAMA* 1983;249(16):2195–8.
- [10] Nappi RE, Kokot-Kierepa M. Women's voices in the menopause: results from an international survey on vaginal atrophy. *Maturitas* 2010;67:233–8.
- [11] Nappi RE, Kokot-Kierepa M. Vaginal health: insights, views & attitudes (VIVA). Results from an international survey. *Climacteric* 2012;15:36–44.
- [12] Goldstein I. Recognizing and treating urogenital atrophy in postmenopausal women. *J Women's Health (Larchmt)* 2010;19(3):425–32.
- [13] NAMS. Management of symptomatic vulvovaginal atrophy: 2013 position statement of The North American Menopause Society. *Menopause* 2013;20(9):888–902.
- [14] Johnston SL, Farrell SA, Bouchard C, Farrell SA, Beckerson LA, Comeau M, et al. The detection and management of vaginal atrophy. *J Obstet Gynaecol Can* 2004;26:503–15.
- [15] Bygdeman M, Swahn M. Replens versus dienoestrol cream in the symptomatic treatment of vaginal atrophy in postmenopausal women. *Maturitas* 1996;23:259–63.
- [16] Rees M, Pérez-López FR, Ceasu I, Depypere H, Erel T, Lambrinoukaki I, et al. EMAS clinical guide: low-dose vaginal estrogens for postmenopausal vaginal atrophy. *Maturitas* 2012;73:171–4.
- [17] Ronconi L, Galli M. MonaLisa Touch™. The latest frontier in the treatment of vaginal atrophy. *Scientific Series, September, vol. 2. DEKA ed.*; 2012.
- [18] Ong MW, Bashir SJ. Fractional laser resurfacing for acne scars: a review. *Br J Dermatol* 2012;166:1160–9.
- [19] Tierney EP, Hanke CW. Fractionated carbon dioxide laser treatment of photoaging: prospective study in 45 patients and review of the literature. *Dermatol Surg* 2011;37:1279–90.
- [20] Peterson JD, Goldman MP. Rejuvenation of the aging chest: a review and our experience. *Dermatol Surg* 2011;37:555–71.
- [21] Berlin AL, Hussain M, Phelps R, Goldberg DJ. A prospective study of fractional scanned nonsequential carbon dioxide laser resurfacing: a clinical and histopathologic evaluation. *Dermatol Surg* 2009;35:222–8.
- [22] Tierney EP, Hanke CW. Ablative fractionated CO₂ laser resurfacing for the neck: prospective study and review of the literature. *J Drugs Dermatol* 2009;8:723–31.
- [23] Capon A, Mordon S. Can thermal lasers promote skin wound healing? *Am J Clin Dermatol* 2003;4(1):1–12.
- [24] De Maio A. Extracellular heat shock proteins, cellular export vesicles, and the Stress Observation System: a form of communication during injury, infection, and cell damage. It is never known how far a controversial finding will go! Dedicated to Ferruccio Ritossa. *Cell Stress Chaperones* 2011;16(3):235–49.
- [25] Baden WF, Walker TA. Physical diagnosis in the evaluation of vaginal relaxation. *Clin Obstet Gynecol* 1972;15:1055–69.
- [26] Brizzolara S, Killeen J, Severino R. Vaginal pH and parabasal cells in postmenopausal women. *Obstet Gynecol* 1999;94:700–3.
- [27] Bachmann G. A new option for managing urogenital atrophy in postmenopausal women. *Contemp Obstet Gynecol* 1997;42:13–28.
- [28] Snoeckx LHEH, Cornelussen RN, Van Nieuwenhoven FA, Reneman RS, Van derVusse GJ. Heat shock proteins and cardiovascular pathophysiology. *Physiol Rev* 2002;81:1461–97.

- [29] Yamasaki A, Tamamura K, Sakurai Y, Okuyama N, Yusa J, Ito H. Remodeling of the rat gingiva induced by CO₂ laser coagulation mode. *Lasers Surg Med* 2008;40:695–703.
- [30] Chen WR, Lu H, Nordquist RE. Mechanism of laser immunotherapy – role of immunoadjuvant and selective photothermal laser – tissue interaction. *Proc SPIE* 2002;4536:82–9.
- [31] Wang S, Diller KR, Aggarwal SJ. Kinetics study of endogenous heat shock protein70 expression. *J Biomech Eng* 2003;125:794–7.
- [32] Verrico AK, Haylett AK, Moore JV. In vivo expression of the collagen related heat shock protein HSP47, following hyperthermia or photodynamic therapy. *Lasers Med Sci* 2001;16:192–8.
- [33] Jiang X, Ge H, Zhou C, Chai X, Deng H. The role of transforming growth factor β 1 in fractional laser resurfacing with a carbon dioxide laser. *Lasers Med Sci* 2014;29:681–7.
- [34] Stenberg A, Heimer G, Ulmsten U. The prevalence of urogenital symptoms in postmenopausal women. *Maturitas* 1995;22(Suppl.):S17–20.
- [35] Ganz PA, Greendale GA, Petersen L, Zibecchi L, Kahn B, Belin TR. Managing menopausal symptoms in breast cancer survivors: results of a randomized controlled trial. *J Natl Cancer Inst* 2000;92:1054–64.
- [36] Gaspar A, Addamo G, Brandi H. Vaginal fractional CO₂ laser: a minimally invasive option for vaginal rejuvenation. *Am J Cosmet Surg* 2011;28:156–62.
- [37] Salvatore S, Nappi RE, Zerbinati N, Calligaro A, Ferrero S, Candiani M, et al. A 12-week treatment with fractional CO₂ laser for vulvovaginal atrophy: a pilot study. *Climacteric* 2014;17:363–9.
- [38] Salvatore S, Digesu G, Siesto G, Serati M, Zerbinati N, Cappellano F, et al. Vaginal collagen remodeling after fractional carbon dioxide laser surgery [abstract 233]. In: Presented at Annual Meeting of the International Continence Society. 2011.
- [39] Ettinger B, Hait H, Reape KZ, Shu H. Measuring symptom relief in studies of vaginal and vulvar atrophy: the most bothersome symptom approach. *Menopause* 2008;15:885–9.
- [40] Longo C, Galimberti M, De Pace B, Pellacani G, Bencini PL. Laser skin rejuvenation: epidermal changes and collagen remodeling evaluated by in vivo confocal microscopy. *Lasers Med Sci* 2013;28:76–9.
- [41] Sadosky R, Basson R, Krychman M, Morales AM, Schover L, Wang R, et al. Cancer and sexual problems. *J Sex Med* 2010;7:349–73.
- [42] Pfeiler GP, Glatz C, Königsberg R, Geisendorfer T, Fink-Retter A, Kubista E, et al. Vaginal estriol to overcome side-effects of aromatase inhibitors in breast cancer patients. *Climacteric* 2011;14:339–44.
- [43] Oni G, Brown SA, Kenkel JM. Can fractional lasers enhance transdermal absorption of topical lidocaine in an in vivo animal model. *Lasers Surg Med* 2012;44:168–74.